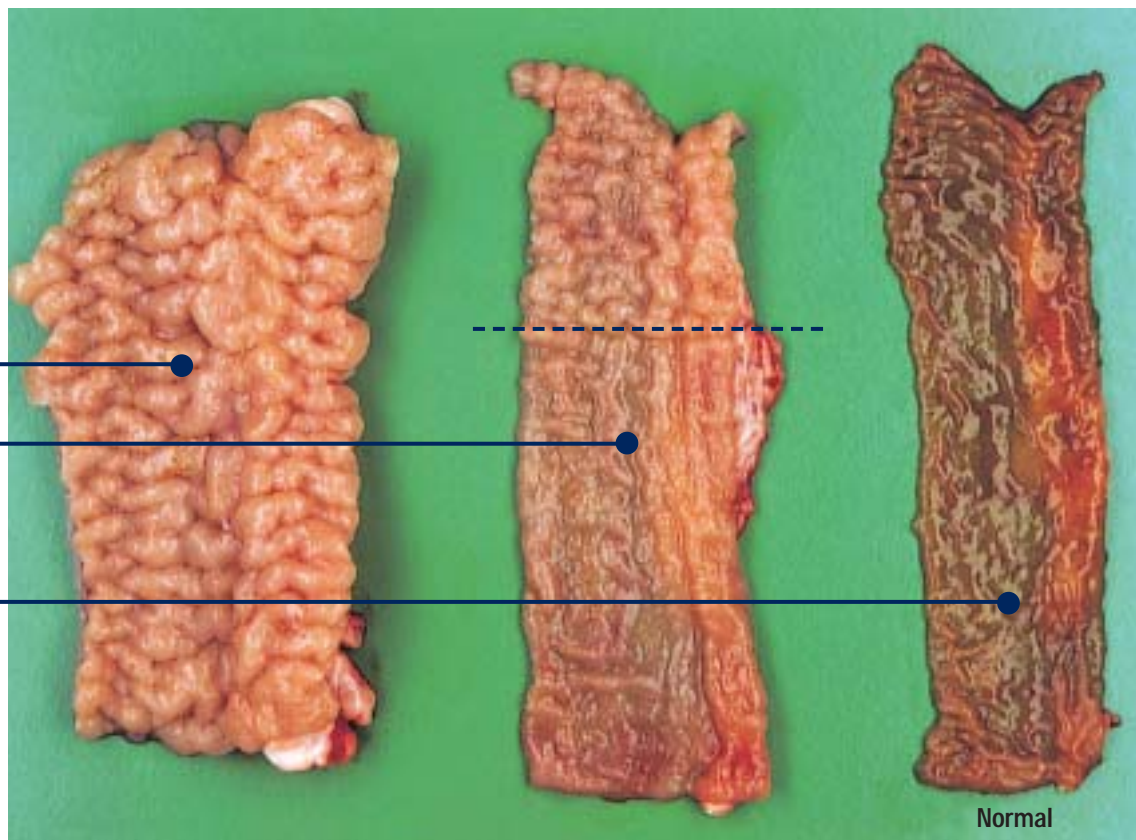


Intestinal lining of an OJD affected sheep >

Note:
the prominent ridges in the severely affected section of the lower small intestine (left), the defined edges of the lesion (centre) and the relatively normal surface of the upper small intestine (jejunum) (right).

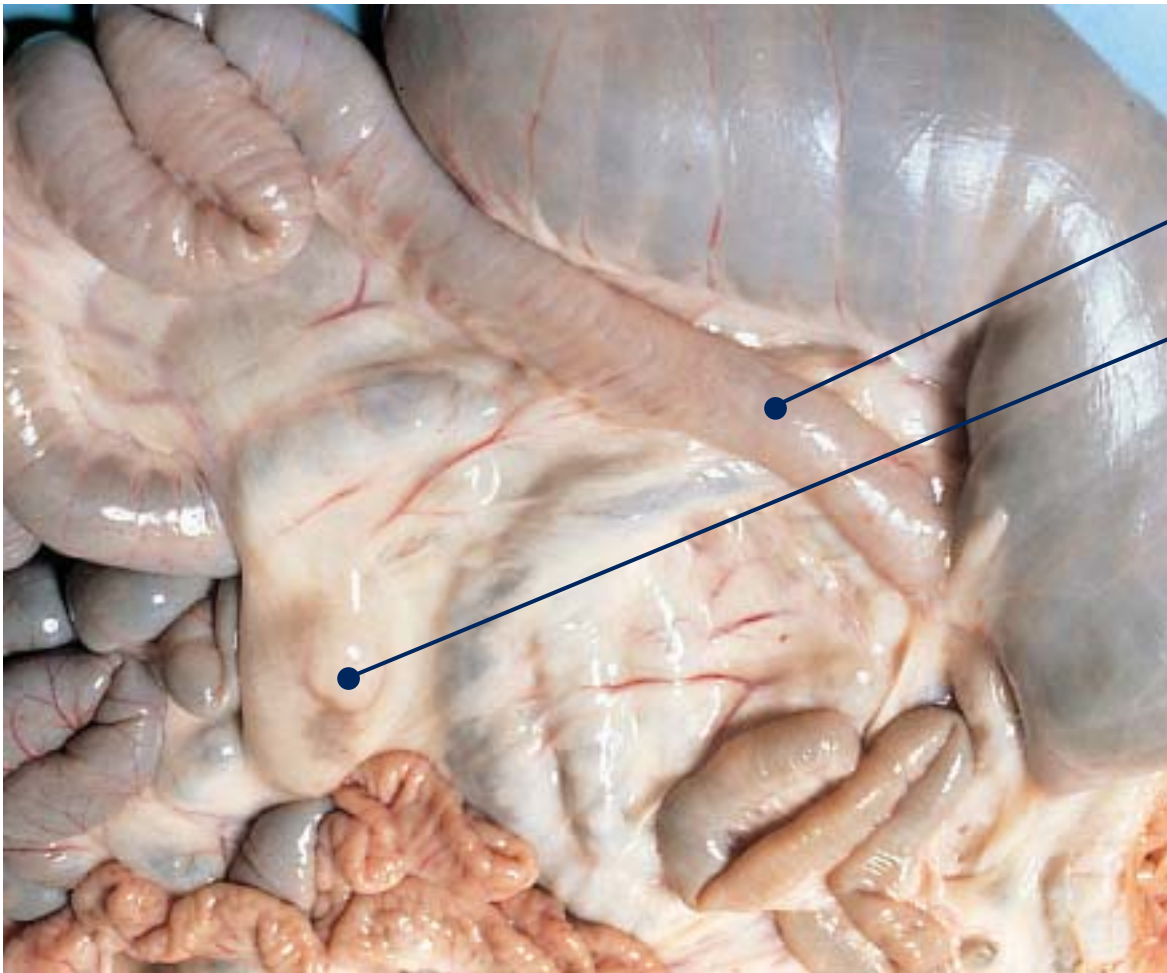


FOR FURTHER INFORMATION CONTACT YOUR VETERINARIAN OR LOCAL ANIMAL HEALTH OFFICER.

Which of these sheep have OJD?

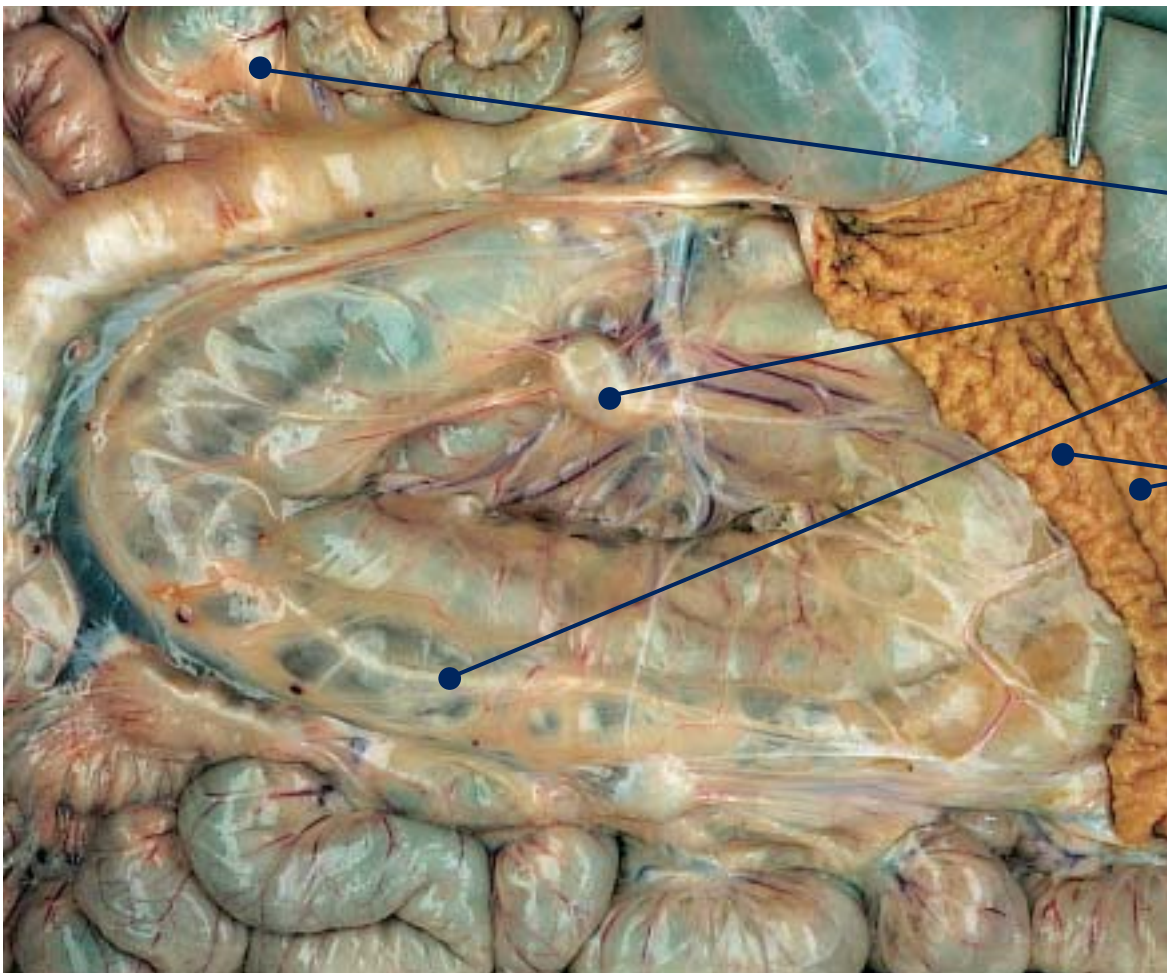


THEY ALL DO:
most sheep shedding
OJD show no clinical signs



< Ileo-caecal area of an OJD affected sheep.

Note:
thickened lower small intestine (ileum) and enlarged lymph nodes.



< Intestinal tract of an OJD affected sheep.

Note:
thickened lower small intestine, enlarged lymph nodes, prominent lymphatic vessels in the membrane and the raised ridges on the lining of the small intestine.